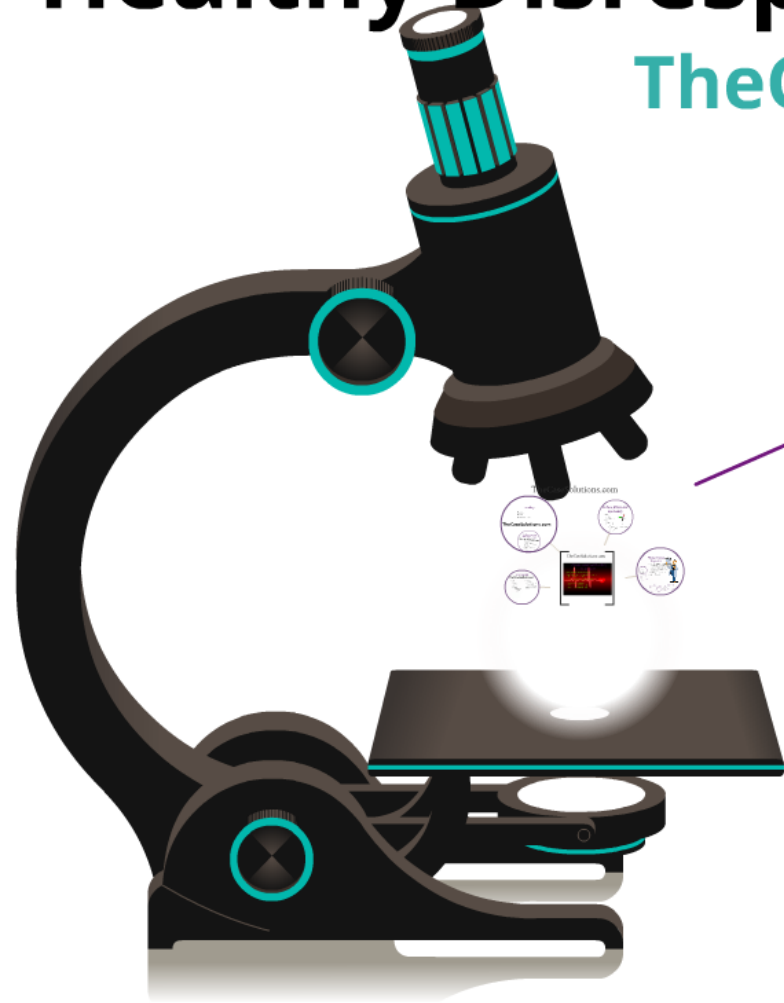


Leadership At General Electric: A Healthy Disrespect For History

TheCaseSolutions.com



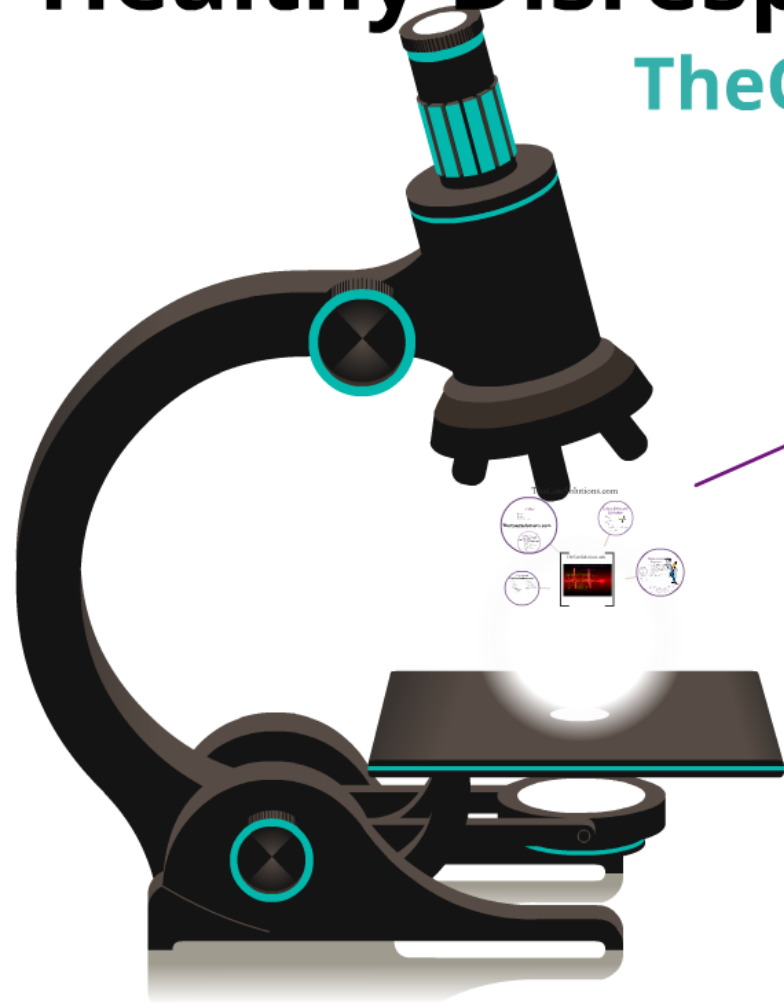
Introduction

- Gentiva
- Sun City West
- D.L.
- 53 years old
- Hispanic
- Male
- 1 week S/P open heart quintuple bypass surgery (9/19/13)
- Used right great saphenous vein
- Main diagnosis: stroke

TheCaseSolutions.com

Leadership At General Electric: A Healthy Disrespect For History

TheCaseSolutions.com



Introduction

- Gentiva
- Sun City West
- D.L.
- 53 years old
- Hispanic
- Male
- 1 week S/P open heart quintuple bypass surgery (9/19/13)
- Used right great saphenous vein
- Main diagnosis: stroke

TheCaseSolutions.com

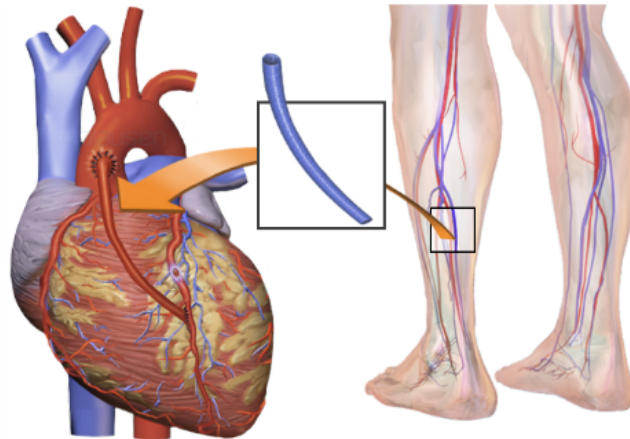
Introduction

- Gentiva
- Sun City West
- D.L.
- 53 years old
- Hispanic
- Male
- 1 week S/P open heart quintuple bypass surgery (9/19/13)
- Used right great saphenous vein
- Main diagnosis: stroke

TheCaseSolutions.com

▪

Open Heart Quintuple Bypass Surgery



TheCaseSolutions.com



TheCaseSolutions.com

Funding

- Medicare
- Railroad
- United Health Care

TheCaseSolutions.com

Significant Functional Health Patterns (SFHPs)

TheCaseSolutions.com



Culture, Ethics, and Spirituality

- Culture
 - i. Diet
 - ii. Gender roles
- Ethics
 - i. Autonomy
 - ii. Beneficence v nonmaleficence
 - 1. Patient's outcome versus frustration/depression/stress
 - 2. Catch-22



Environment

TheCaseSolutions.com

- Family
 - 1. Wife
 - 2. Sister
 - 3. 10 children
- Culture
 - 1. Spanish
 - 2. Catholic
 - 3. Traditional cooking
 - 4. Agribusiness
 - 5. Gender role patriarchal
- Environmental factors
 - 1. San City West
 - 2. Property 2,915-3,000 sq ft
 - 3. 1/2 acre lot
 - 4. Average, brick/stone high average size (2400, 3000)
 - 5. No pool



TheCaseSolutions.com

Physical Assessment/Charting by Exception

- Strong heart beat, not +4 bounding pulse
- 18 cm sternum wound, approximately scabbing, no significant drainage/exudate
- T-E2 -> 10 cm x 10 cm, approximately 10 cm, no significant drainage/exudate
- Medial aspect of right leg
- Medial aspect of right popliteal
- Medial aspect of right inguinal



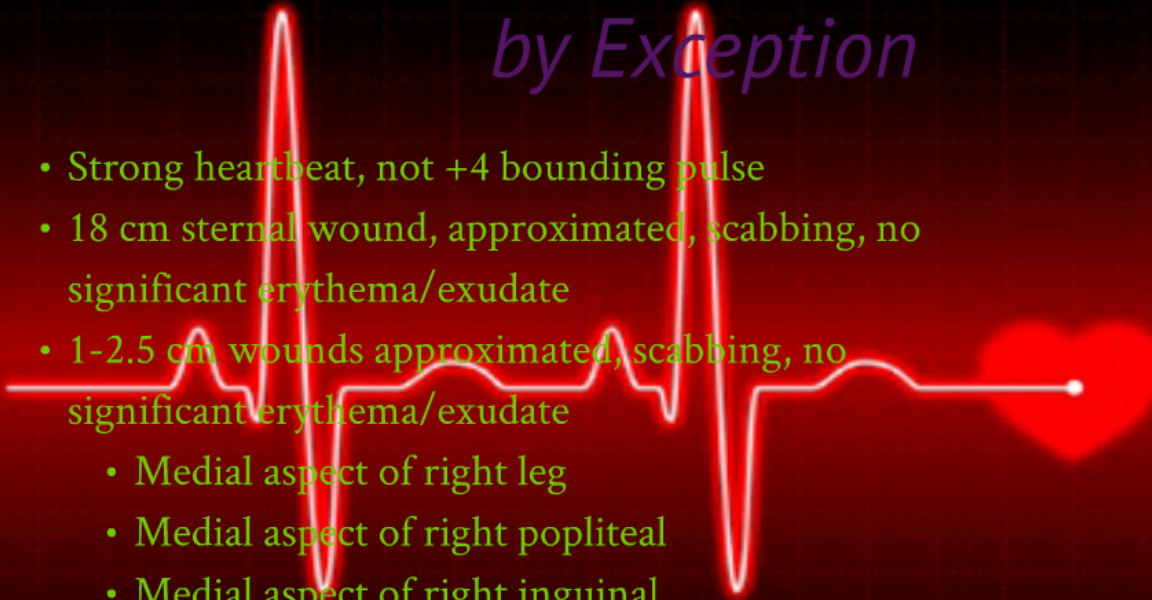Priority Nursing Diagnoses

- Cognitive/Perceptual (Carpenter's rule)
- Knowledge deficit related to low self-esteem evidenced by verbalizing having "no control" over internal ADLs
- Health Perception/Management
- Nutrition/Meal/Intake



Physical Assessment/Charting by Exception

- Strong heartbeat, not +4 bounding pulse
- 18 cm sternal wound, approximated, scabbing, no significant erythema/exudate
- 1-2.5 cm wounds approximated, scabbing, no significant erythema/exudate
 - Medial aspect of right leg
 - Medial aspect of right popliteal
 - Medial aspect of right inguinal



Environment

TheCaseSolutions.com

- Family

1. Wife
2. Sister
3. No children

- Culture

1. Hispanic
2. Traditional cooking
3. "Whole" ingredients
4. Gender role: patriarchal



- Environmental factors

1. Sun City West
2. Property 2,500-3,000 sq ft +/- outside amenities
3. Average, borderline high average size (NPR, 2013)
4. No pets



Funding

- Medicare
- Railroad
- United Health Care

TheCaseSolutions.com

Significant Functional Health Patterns (FHPs)

TheCaseSolutions.com




- Health Perception/Management
 - i. "New heart"
 - ii. Feels able to return to normal and more
 - iii. Does not feel tired with exertion but vitals increase significantly
- Nutrition/Metabolic
 - i. "Whole ingredients"
 - ii. Bacon
 - iii. Temporary versus permanent diet change
- Cognitive/Perceptual
 - i. Did not finish college
 - ii. New self
 - iii. Surgeon: "Good as new"



Significant Functional Health Patterns (FHPs)

TheCaseSolutions.com



- Health Perception/Management
 - i. “New heart”
 - ii. Feels able to return to normal and more
 - iii. Does not feel tired with exertion but vitals increase significantly
- Nutrition/Metabolic
 - i. “Whole ingredients”
 - ii. Bacon
 - iii. Temporary versus permanent diet change
- Cognitive/Perceptual
 - i. Did not finish college
 - ii. New self
 - iii. Surgeon: “Good as new”

